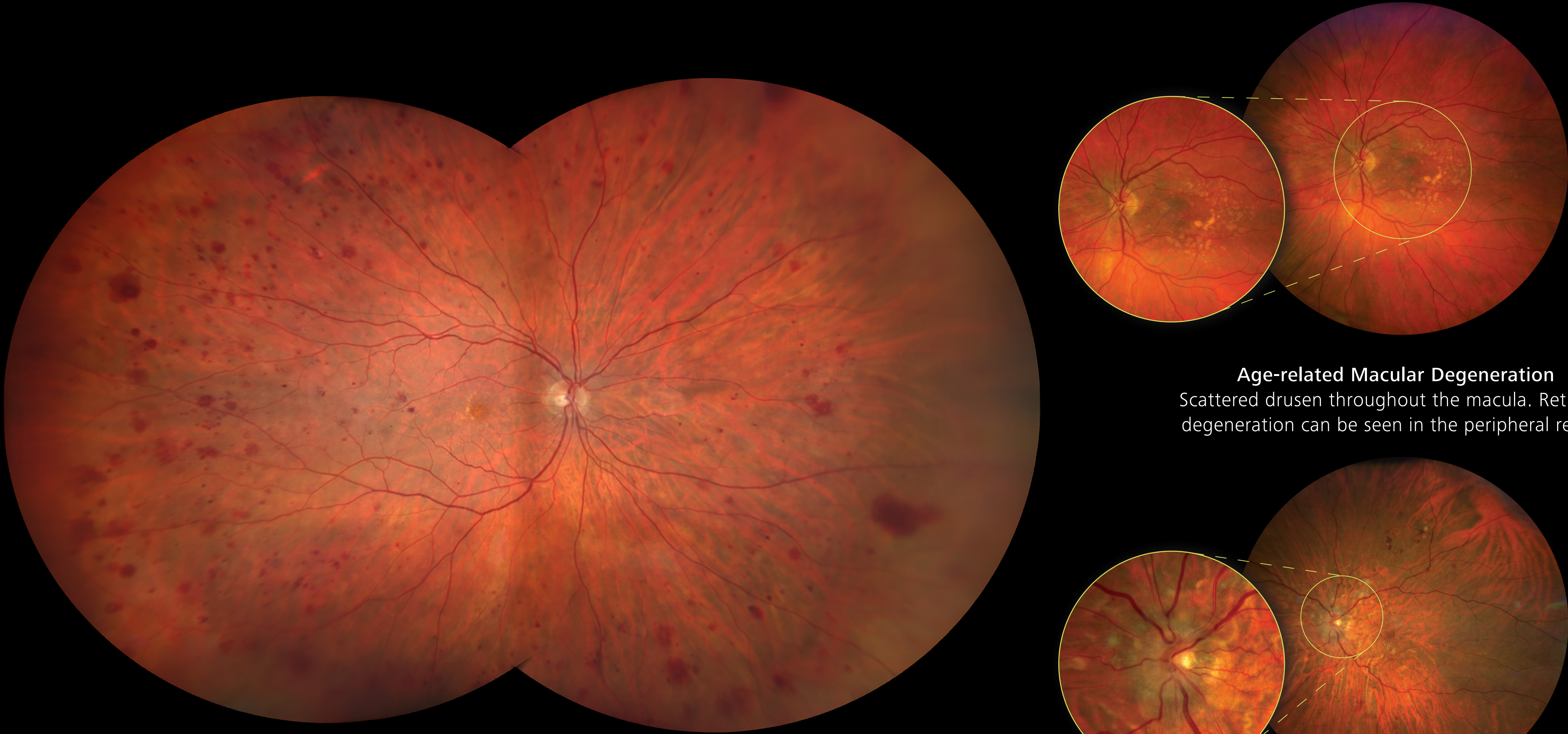
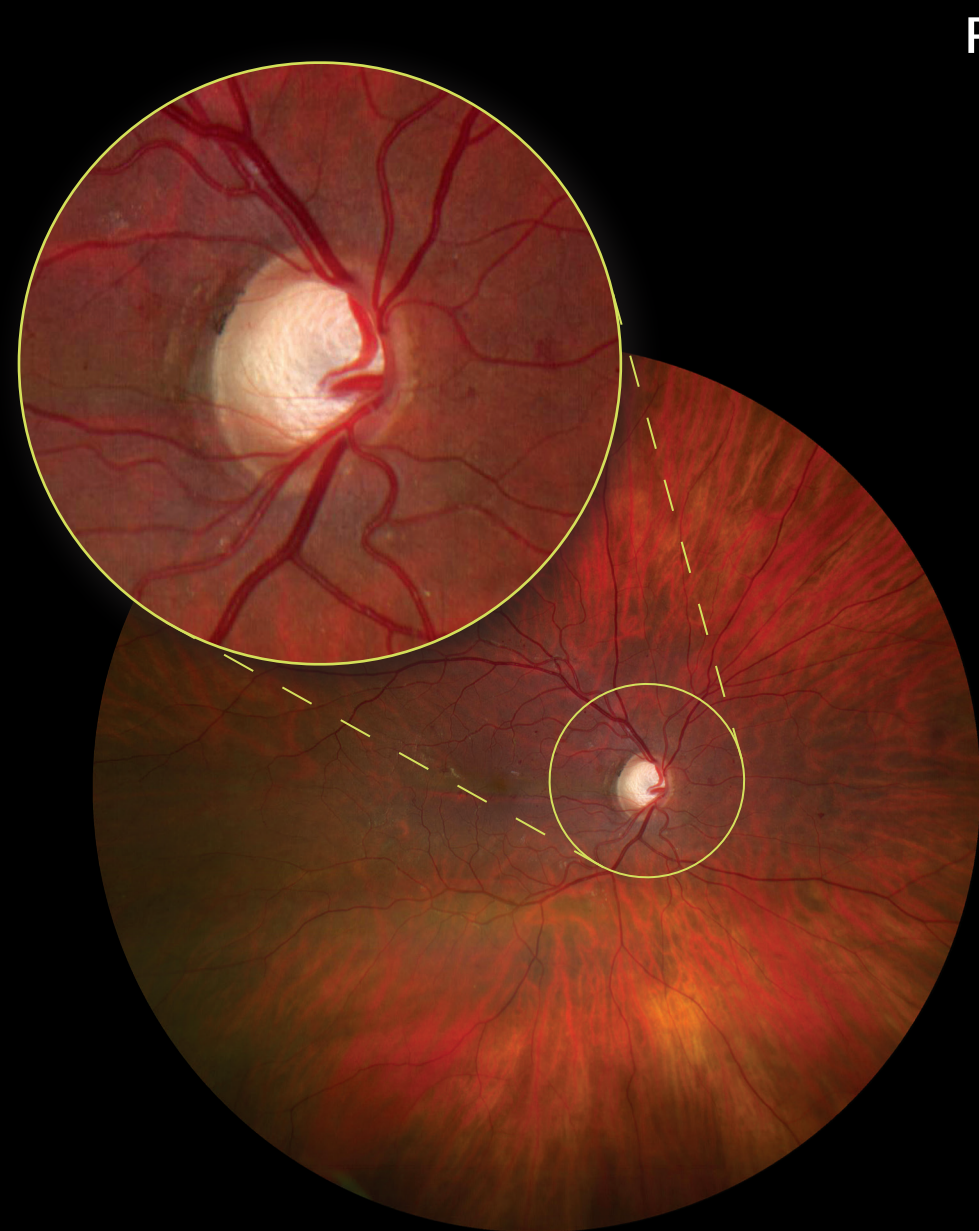

Revealing more with Ultra-widefield fundus exams

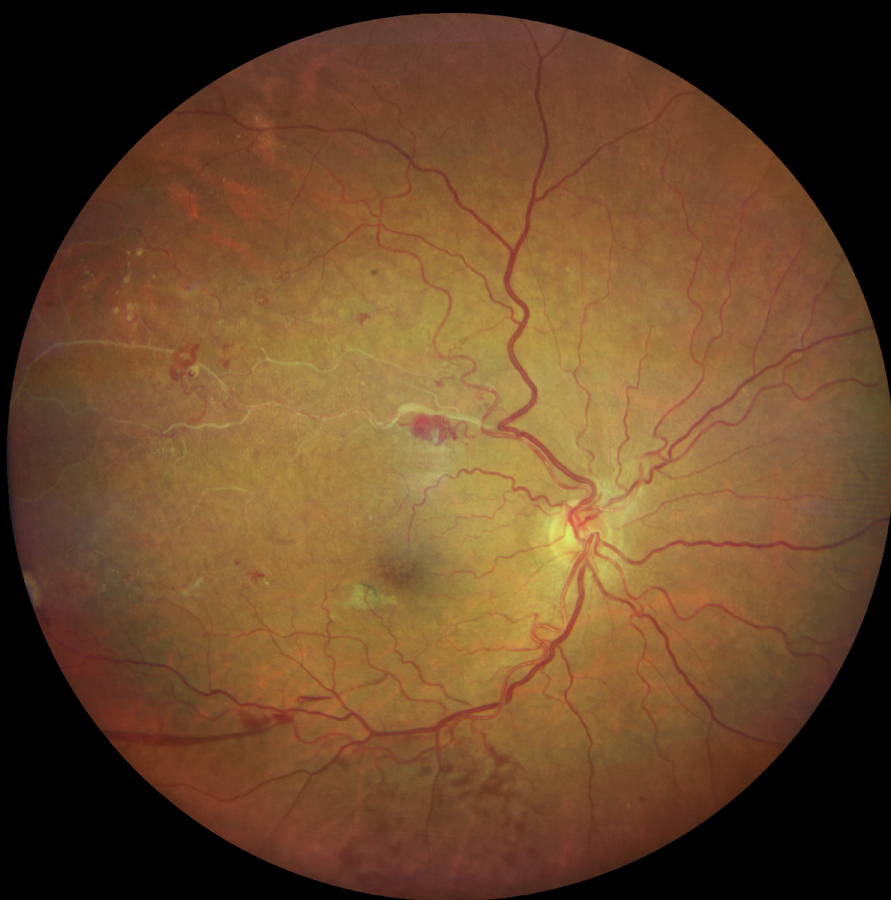Images courtesy of Roger A. Goldberg, MD, MBA, Jesse Jung, MD, Jean-Francois Korobelnik, MD and the ZEISS imaging database



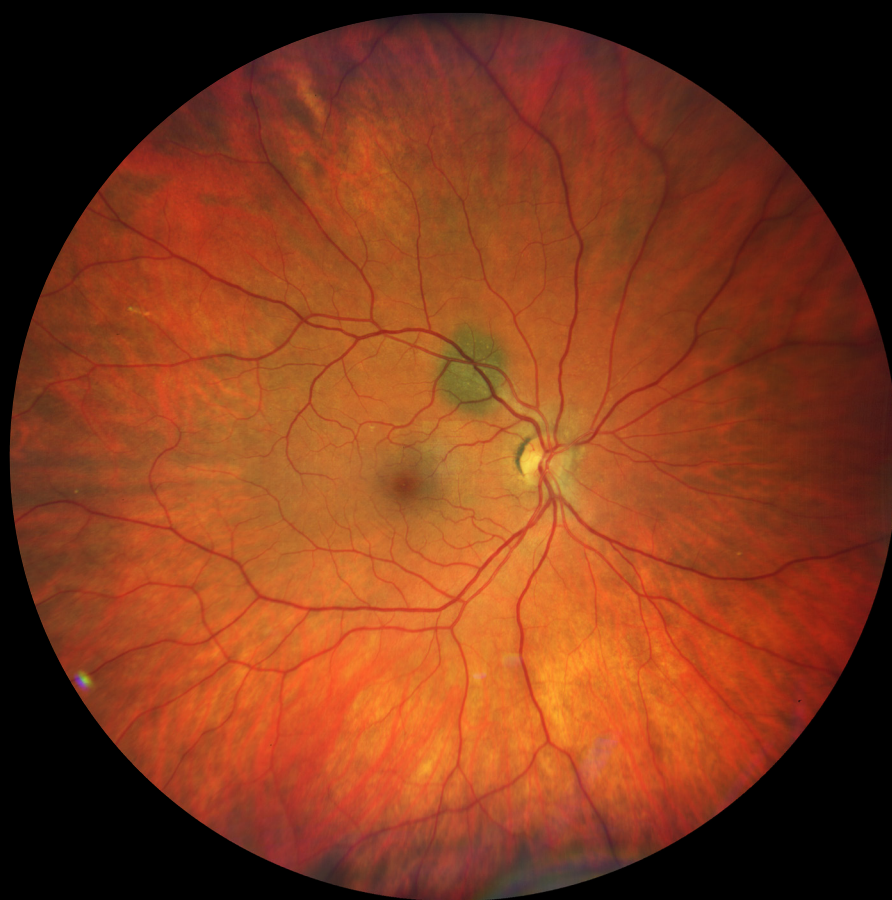Age-related Macular Degeneration
Scattered drusen throughout the macula. Reticular degeneration can be seen in the peripheral retina.



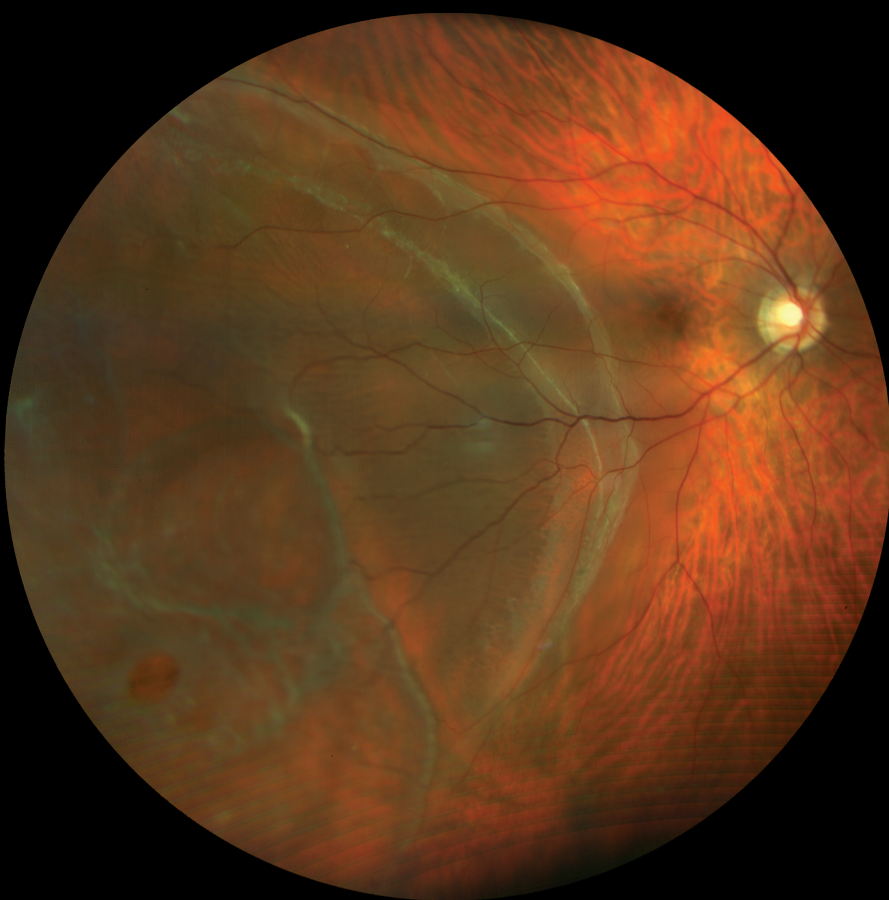
Proliferative Diabetic Retinopathy



Glaucoma

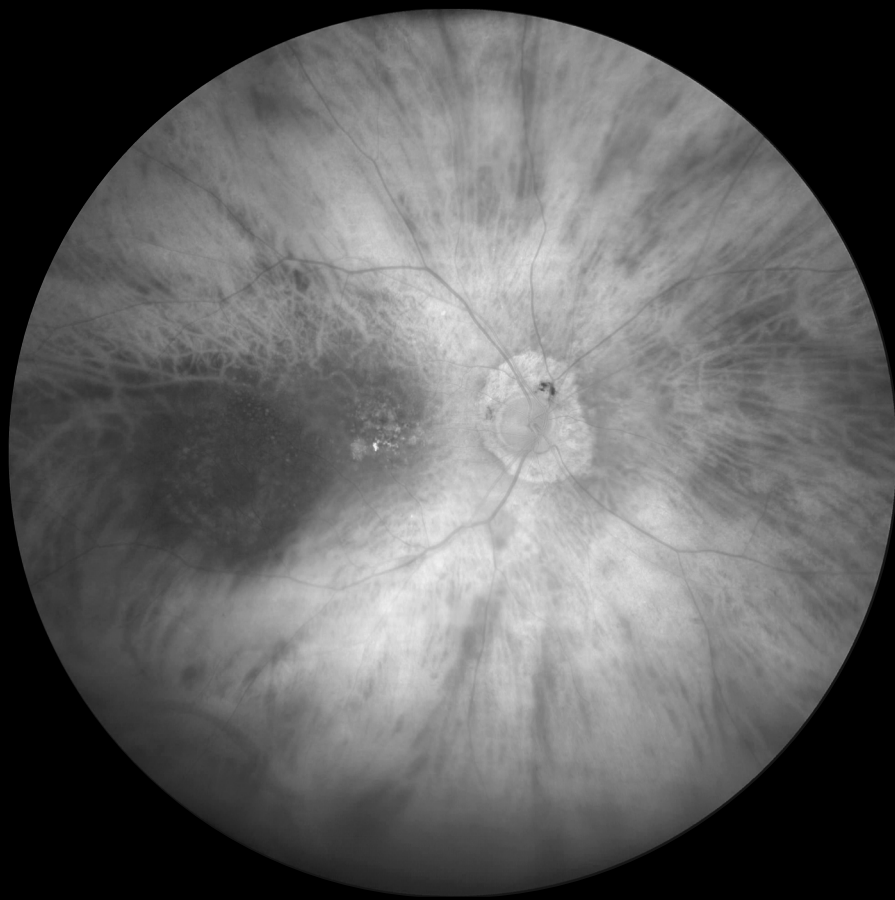


Branch Retinal Vein Occlusion

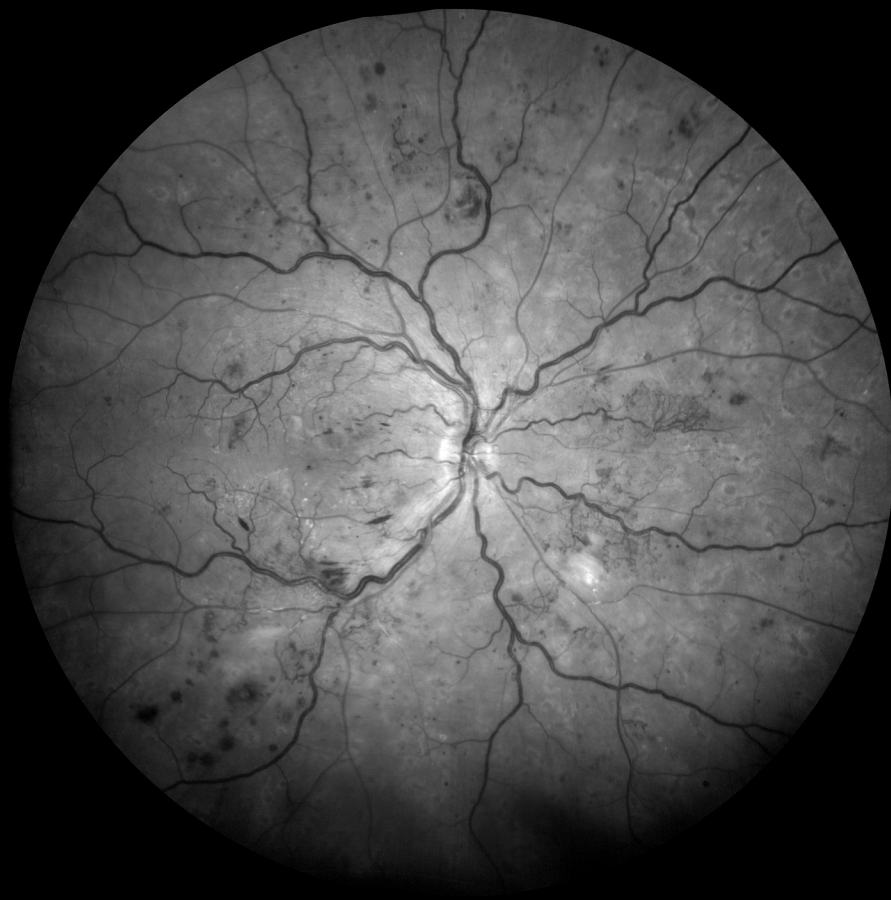

Retinal Detachment

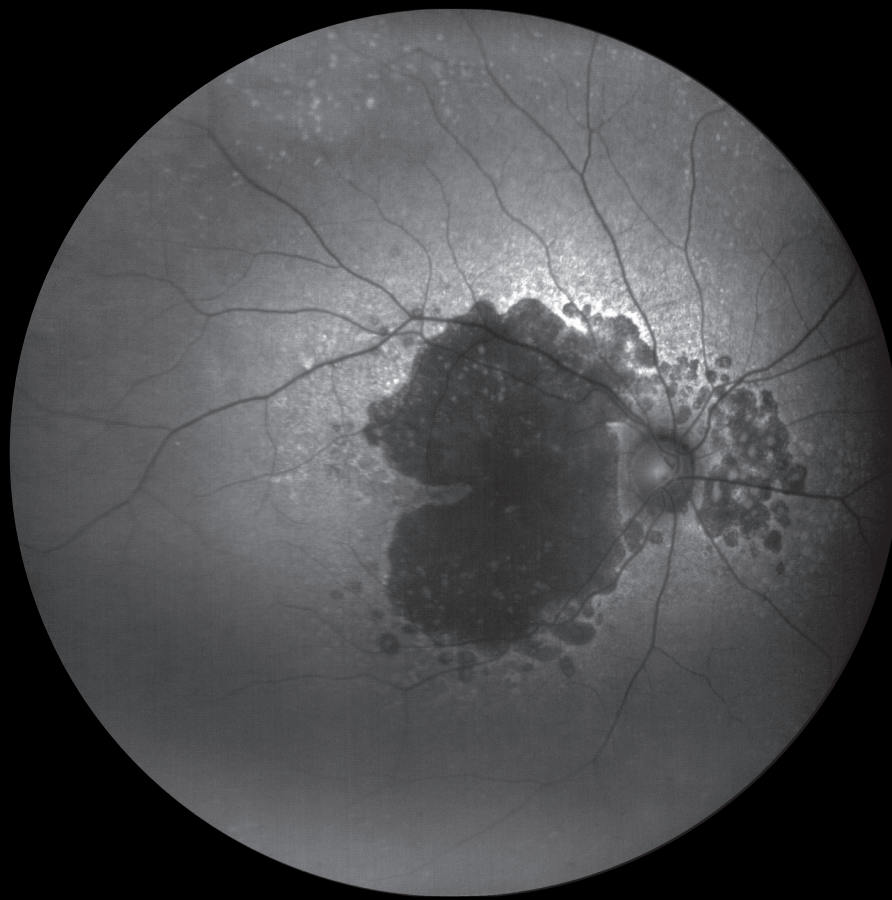
Imaging Modalities



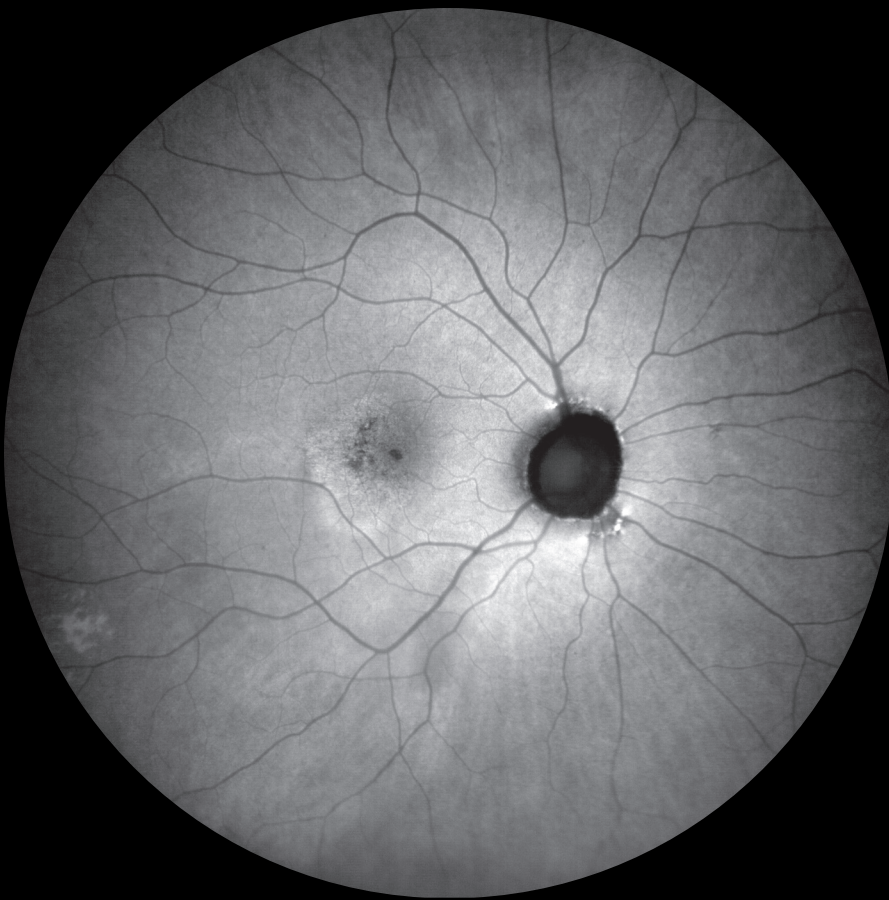Choroidal Nevus
Red channel separation



Proliferative Diabetic Retinopathy
Green channel separation

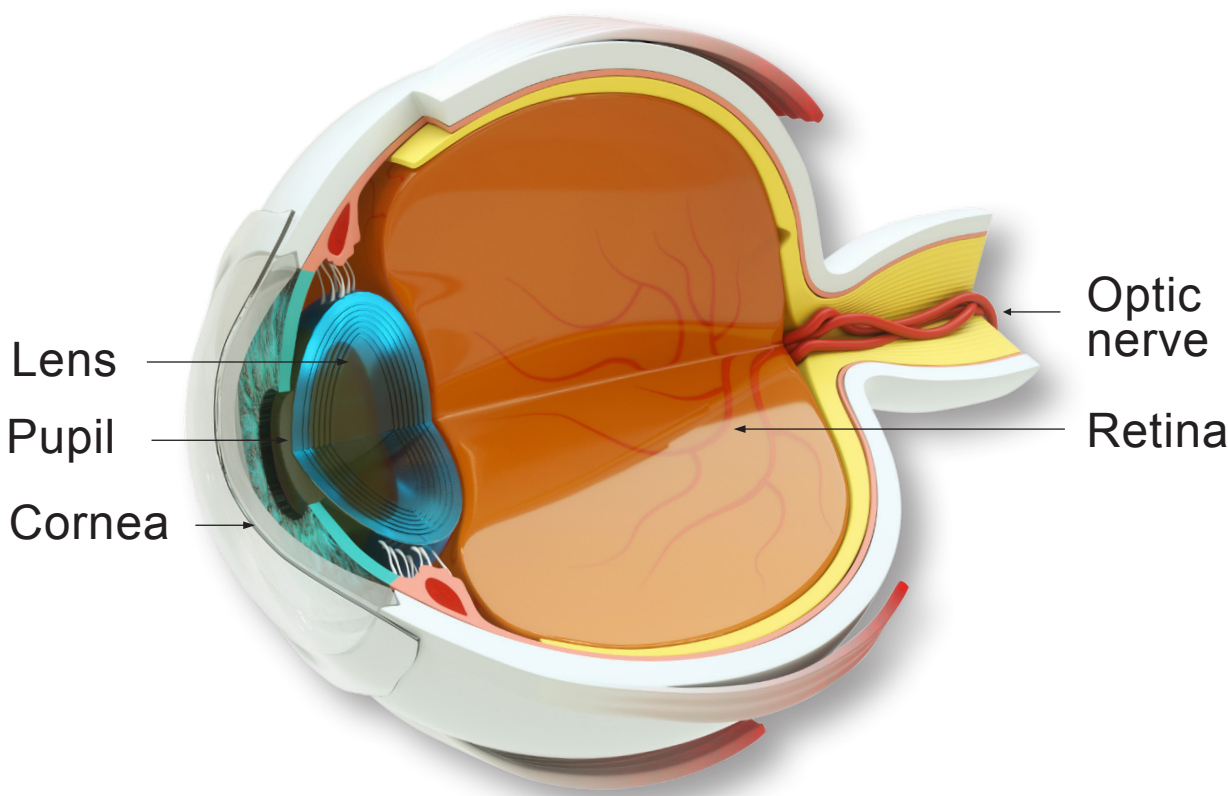


Geographic Atrophy
FAF-Blue



Dry Age-related Macular Degeneration
FAF-Green

EN_31_050_00121



Ultra-widefield fundus exams allow for comprehensive assessment of the health of your eyes for early detection and aiding in management of eye disease. Take charge of your eye health. Ask your doctor about the ultra-widefield fundus exam.

